

PARASITES OF SMALL MAMMALS IN GRAND TETON NATIONAL PARK: *Babesia* and *Hepatozoon*

SUZANNE E. MOSHIER ♦ WILLIAM D. O'DELL ♦ RAYCHEL A. WATKINS
DEPARTMENT OF BIOLOGY ♦ UNIVERSITY OF NEBRASKA ♦ OMAHA

AELITA J. PINTER ♦ DEPARTMENT OF BIOLOGICAL SCIENCES
UNIVERSITY OF NEW ORLEANS ♦ NEW ORLEANS

♦ INTRODUCTION

In a review of the parasites of *Microtus*, Timm (1985) lists no protozoan endoparasites whatsoever for this genus. The role of parasitism, whether macro- or microparasites, and whether endo- or ectoparasites, in the demographic machinery of microtines is poorly understood. Timm (1985) astutely observes that one of the most challenging and fruitful directions of future research with *Microtus* will be the statistical quantification of the cost of parasitism. In addition, since humans in the Grand Teton National Park may encounter protozoan parasites that are potentially pathogenic to humans, it is useful to characterize the occurrence and biology of such organisms in the park.

Babesia microti, a parasitic protozoon, is transmitted by a tick vector and reproduces in the erythrocytes of its mammalian host. Initially, *Babesia* was thought to be restricted to small mammals; however, in 1970 the first human cases were diagnosed in residents of Nantucket Island, Massachusetts (Western et al, 1970). Over 200 cases of human babesiosis have been documented worldwide. In the United States, human babesiosis is caused by *B. microti*. Most of these cases have occurred in the eastern United States. The earliest report of an organism that fits the description of *Babesia* in human erythrocytes is that of Wilson et al. (1904), who found an unknown organism in

human erythrocytes while investigating the cause of Rocky Mountain Spotted fever. Documented cases of babesiosis in many areas of the United States are increasing (Steketee et al, 1985). As humans insert themselves into places where they have historically been present only occasionally, they often contract new diseases.

A second protozoon parasite, *Hepatozoon* sp., which is widespread in small mammals in Europe, is also found in reptiles throughout the world. The record of *Hepatozoon* in North American small mammals is not extensive. Fewer than 10 species of mammals have been shown to harbor *Hepatozoon* parasites. Like *Babesia*, *Hepatozoon* is a two-host parasite. Unlike *Babesia*, for which the intermediate host is always a tick, the intermediate host in the *Hepatozoon* may be a tick, a mite, a flea, or a mosquito. The method of transmission by the vector also differs in the two parasites. *Babesia* is transmitted in saliva when the tick bites, whereas *Hepatozoon* infection requires the vertebrate host to swallow the vector.

In our 1994 studies, we sought to extend knowledge of these two parasites. The specific objectives for 1994 were: to sample specific populations of *M. montanus*, in which we have previously documented *Hepatozoon* infections, to determine whether there are differences in the infection rates at different study sites in the park; to

search for the vector of *Hepatozoon* sp. infections in *M. montanus* by examining ectoparasites; to collect and rear ticks from *M. montanus* for use in *B. microti* transmission studies; and to complete a comparison of the spleen histology of babesiosis in infected and uninfected laboratory animals, with inclusion of data from wild animals, as available. Our long-term objectives are to document the effects and cost of parasitism on vole populations and to determine the potential of small mammals of Grand Teton National Park to serve as reservoirs of human parasites.

◆ METHODS

All animals were trapped at sites within the boundaries of Grand Teton National Park using Sherman live-traps. They were euthanized, a 25 gauge needle was inserted into the left ventricle of the heart, and blood was collected in a heparinized tuberculin syringe. The blood was transferred to a micro-centrifuge tube. Several slides of peripheral blood smears were made from this blood, fixed in methanol, and stained with Wrights-Giemsa stain. The peripheral blood smears were examined for a minimum of 15 minutes each for the presence of *Babesia*, *Hepatozoon*, and other parasites.

Two capillary tubes of blood were centrifuged in a micro-hematocrit centrifuge for five minutes and the hematocrit value was determined from a reader. Reticulocyte counts were done using a Becton-Dickson Unopette Test 5821. Serum was collected from the blood in the micro-centrifuge tubes after centrifugation and stored frozen for future use.

The spleen, liver, lungs, and brain were removed. The spleen and liver were weighed and measured. Impression and squash smears of the organs were made and examined for the presence of parasites, especially for the schizonts of *Hepatozoon*, with a light microscope equipped with 15x oculars and a 100x oil objective. Extra slides were made and fixed in methanol and stained as with the peripheral blood smears. The remaining portions were stored in 10% buffered formalin until preparation for histological examination.

Fleas were collected from the live-trapped animals. They were either squashed and examined with a light microscope for the presence of oocysts, or they were placed in 70% ethanol and later sent to

Dr. Robert E. Lewis at Iowa State University to be identified. Slides positive for the oocysts were stained and photographed using Kodak or Fuji professional tungsten light film, ASA 64.

Ticks were collected from the live-trapped animals. The ticks were maintained on a medium consisting of a mixture of activated charcoal and plaster of Paris until needed for the transmission studies. After the tick had laid eggs and they had hatched, the larvae were allowed to feed on experimentally infected *M. montanus* and then, following molting, they were allowed to feed on uninfected animals. Alternatively, when uninfected *M. montanus* were unavailable, an attempt was made to have the ticks attach to and feed from either a hamster or a white mouse.

To monitor the parasitemia, thin blood smears were prepared from each vole twice a week for up to 3 weeks post-infection. The tip of the tail was snipped with sharp iris scissors to get a drop of blood for a smear. Any animals showing signs of distress associated with the infection were to be euthanized immediately.

The Animal Review Committee of the University of Nebraska Medical Center/University of Nebraska at Omaha has approved a protocol for the transmission studies in voles, for the collections, and for the spleen histology studies (ARC# 89-138-05, ARC# 90-039-12 and ARC#91-063-03).

The permit to collect in Grand Teton National Park was granted to one of us (AJP).

◆ RESULTS AND DISCUSSION

Table 1 shows the results of trapping for 1988 through 1994. The extremes of infection rate for *Babesia microti* both occurred in 1991 when there was a low of 25.7% in the summer and a high of 73.9% in the spring. Each year the spring rate of infection is higher than that of the summer, a finding which is consistent with *Ixodes eastoni's* being a nest tick (personal communication, Richard G. Robbins) and *M. montanus'* living in the same nest until spring, with no dispersal occurring until the onset of the spring snowmelt and the breeding season. The infection rate in the voles is consistently high; nevertheless, we are aware of no human cases of babesiosis contracted from ticks in the Grand Teton National Park. To our knowledge,

I. eastoni is not known to have transmitted *B. microti* to any human. This, too, may be due, at least in part, to *I. eastoni*'s being a nest tick and, therefore, having little opportunity to encounter humans.

Table 1. Incidence of *Babesia microti* and *Hepatozoon* sp. in *Microtus montanus*

Year	Season	Number caught	Number positive		Per cent positive	
			<i>Babesia</i>	<i>Hepatozoon</i>	<i>Babesia</i>	<i>Hepatozoon</i>
1994	Spring	9	5	0	55.6	--
	Summer	59	27	0	45.8	--
1991	Spring	23	17	4	73.9	17.4
	Summer	74	19	5	25.7	6.8
1990	Spring	16	9	0	56.3	--
	Summer	58	19	5	32.8	8.6
1989	Spring	35	16	12	45.7	34.3
	Summer	34	13	1	38.2	2.9
1988	Spring	20	13	0	65.0	--
	Summer	53	16	9	30.2	17.0

We have not yet completed our histological examination of the spleens and other organs of *Babesia*-infected *M. montanus*. This work is in progress.

Hepatozoon sp. is the other endoparasite of *M. montanus* we studied in 1994. The infection rates for 1994 and previous collection years are displayed in Table 1. Rates of infection of *M. montanus* with *Hepatozoon* are characteristically lower than with *B. microti*. One of our goals for several years, and a specific goal for the grant period, was to identify the invertebrate host. We had hypothesized initially that a flea was the invertebrate host and vector of *Hepatozoon* sp. because fleas are established vectors for European small mammals. After finding no oocysts in flea squashes from 1989-1991, we began to plan to examine also *I. eastoni*, which is the most frequently encountered ectoparasite of *M. montanus*, for oocysts to see whether in this instance a tick, rather than a flea, is the invertebrate host. Ticks, fleas, and mites are the only ectoparasites we have found on the voles. Since mites are the least frequently encountered, we considered them the least likely candidates. This year, however, our search yielded 2 fleas containing *Hepatozoon* oocysts and corroborated our original hypothesis. We follow in the footsteps of Desser et al. (1995),

who said, "The discovery of the definitive host of *Hepatozoon catesbianae* was a slow and laborious process that began several years ago with the identification of 3 hematophagous invertebrates that feed on bullfrogs in the study area." We have examined fleas, mites, and ticks for 5 years looking for the oocysts of the *Hepatozoon*. The flea collected in May, 1994, that contained what we have identified morphologically as oocysts of *Hepatozoon* sp. came from an *M. montanus* trapped at a site near an ox bow. The second flea, collected in August, 1994, was removed from an *M. montanus* trapped at the same site. Figures 1, 2, and 3 show oocysts, sporocysts, and sporozoites of *Hepatozoon* sp. in a flea. More fleas containing the oocysts need to be found, identified to the species level, and then fed to uninfected *M. montanus* in a transmission study. The recovery of gametocytes in the blood or schizonts in the lungs would establish that these fleas are vectors of this *Hepatozoon*.

In 1994 we trapped no voles with *Hepatozoon* sp. infections. We attribute this failure to the low population of voles (personal communication, A. J. Pinter). Previously, we have found *Hepatozoon* sp. infections in 3 additional species of small mammals trapped in Grand Teton National Park in 1988 through 1990 (Watkins et al., 1992). Three of the four species, *M. montanus*, *M. pennsylvanicus*, and *Thomomys talpoides*, are newly recognized hosts in North America. The fourth species, *P. maniculatus*, (Figure 13) previously was found infected with *Hepatozoon* in California, but until now, not in Wyoming.

We identified gametocytes in the mononuclear cells of blood smears from all 4 species and in a basophil in the liver of *T. talpoides* (Figures 14-17). In *T. talpoides* and *M. montanus* gametocytes were found also in the spleen (Figure 13), liver (Figure 17), and lungs, but not in the bone marrow. In *T. talpoides* schizogony was always in the liver, while in *M. montanus* it was predominantly in the lungs and rarely in the spleen or liver (Figures 4-11). In neither of these species was schizogony observed in the bone marrow. As did previous investigators, we observed macroschizonts and microschorizonts. Vermicules were observed in lung squash preparations from *M. montanus* only (Figure 12).

Hepatozoon sp. infections were found in *M. montanus* from 8 study sites. Some sites appeared to have a higher infection rate than other

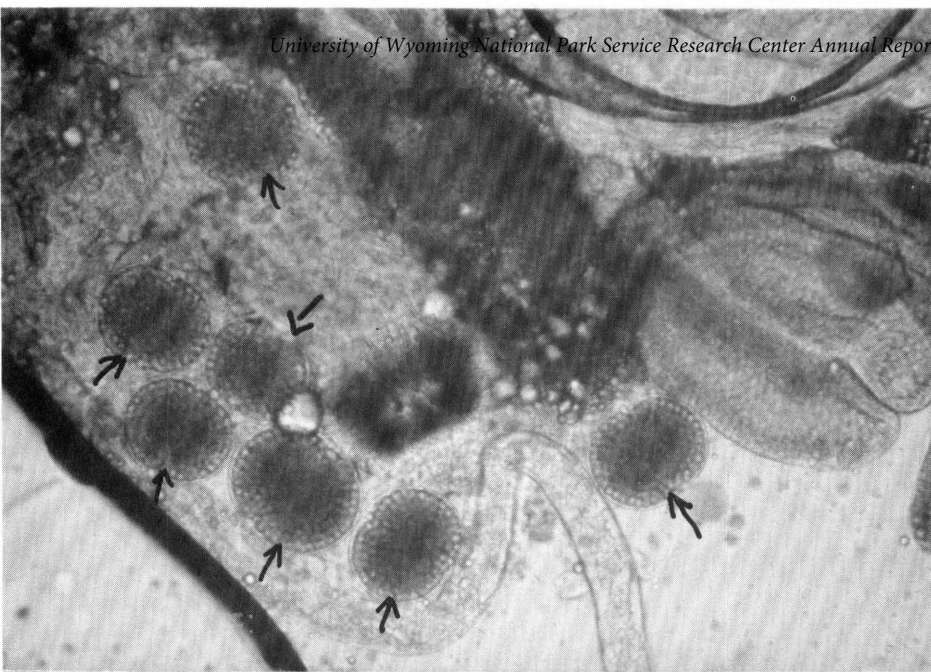

Figure 1. Oocysts of *Hepatozoon* sp. found in a flea squash. X160.

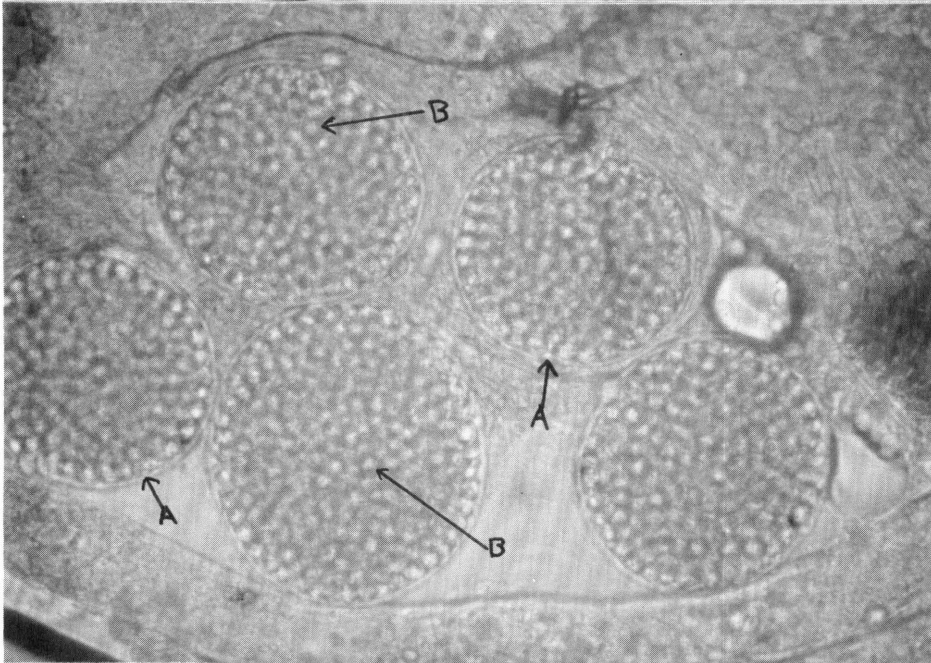


Figure 2. Oocysts (A) of *Hepatozoon* sp. in a flea squash. Numerous sporocysts (B) are visible. X320

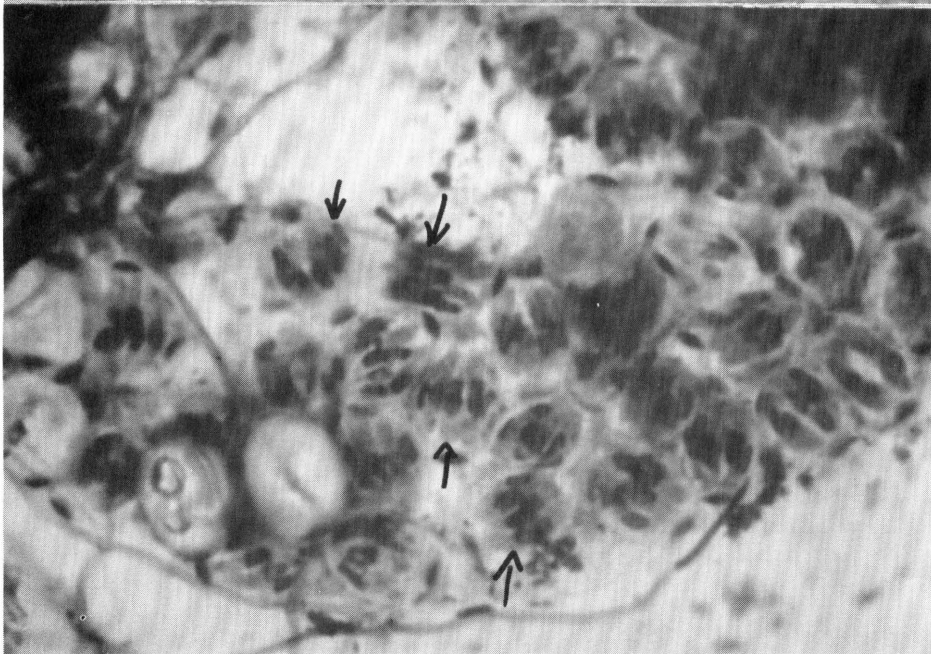


Figure 3. A squashed oocyst of *Hepatozoon* sp. in a flea squash. Each sporocyst contains 4-6 sporozoites. Wrights-Giemsa stain, X1,600.

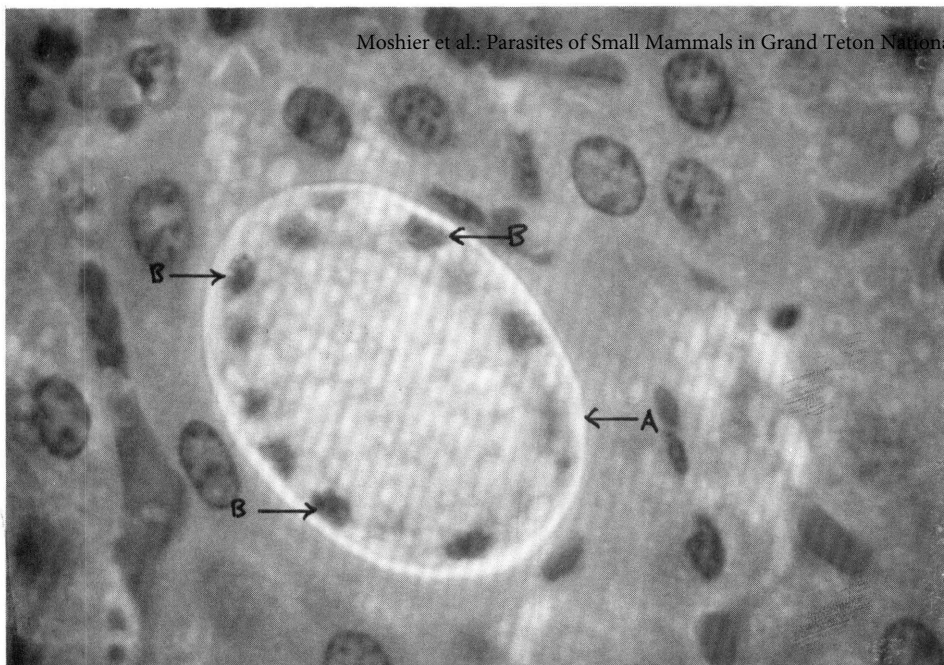


Figure 4. *Hepatozoon* sp. schizont (A) in a thin section of a *Thomomys talpoides* liver. H & E stain, X1,600, B = nuclei.

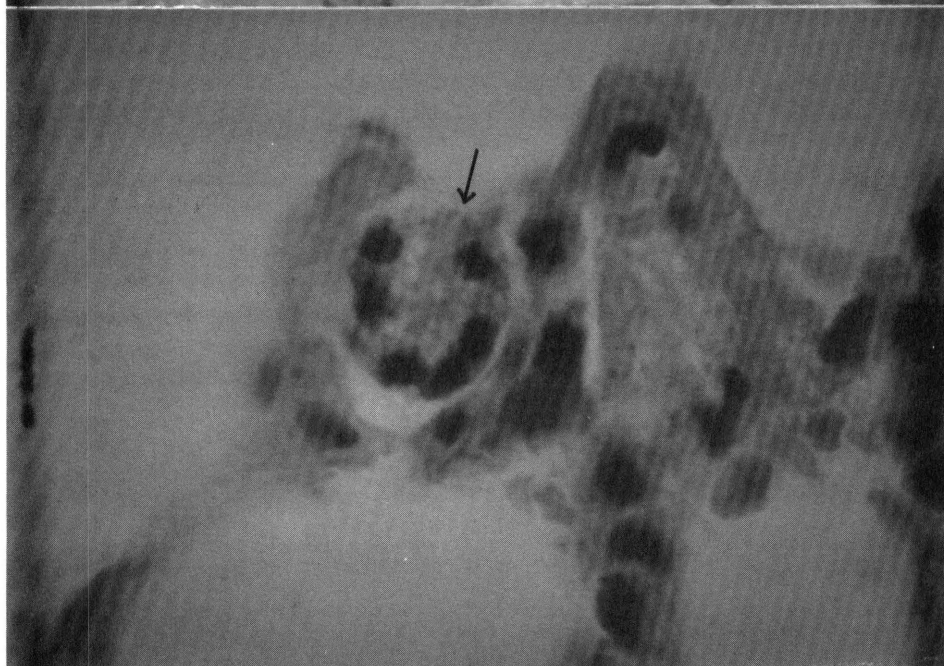

Figure 5. *Hepatozoon* sp. schizont with 6 vermicules in a thin section of a *Microtus montanus* lung. H & E stain, X1,600

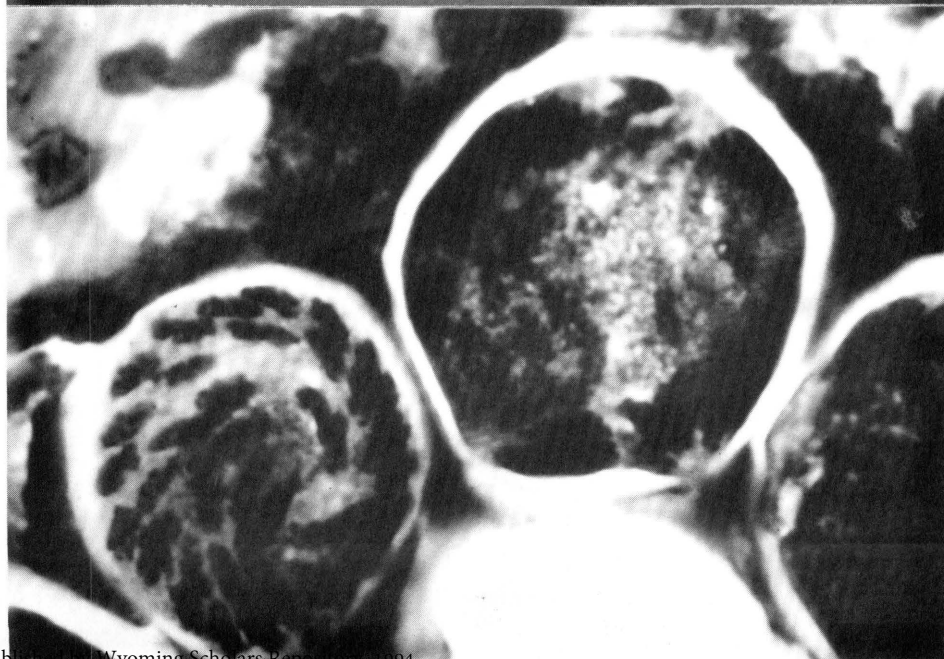


Figure 6. Lung squash of *Microtus montanus* with all of 2 schizonts, and part of a third, in different stages of development. Wrights-Giemsa stain, X1,600.

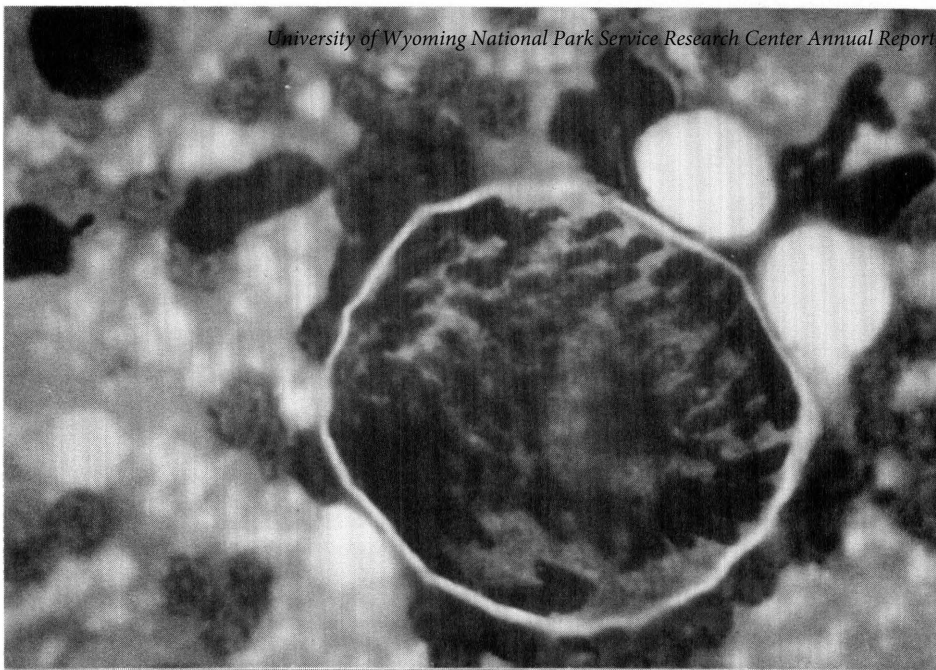

Figure 7. Squash preparation of *Microtus montanus* lung showing a macroschizont with many developing vermicules. Wrights-Giemsa stain, X1,600.

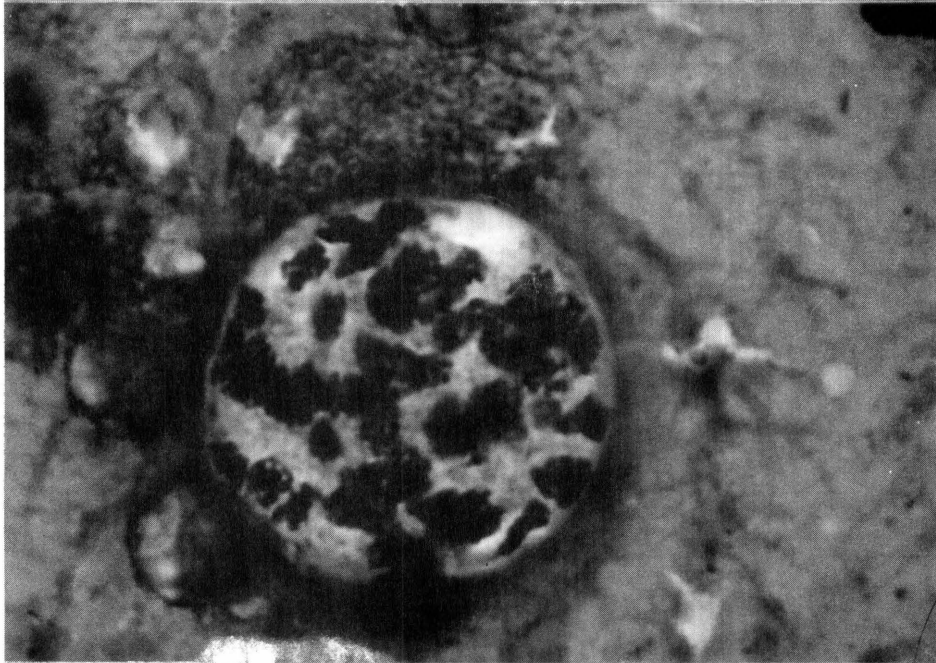


Figure 8. Schizont in a liver squash, *Thomomys talpoides*. Wrights-Giemsa stain, X1,600

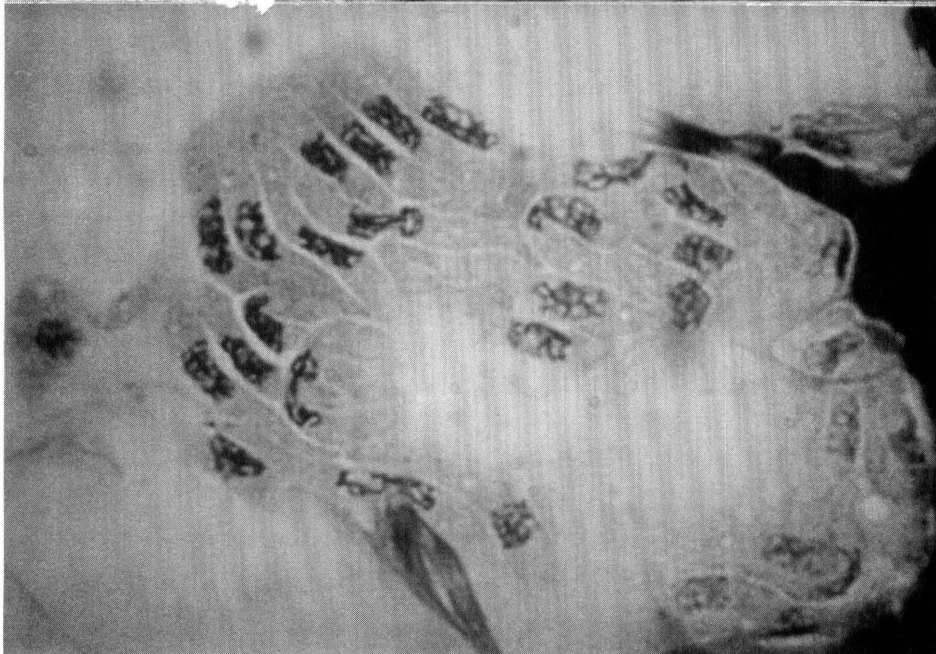

Figure 9. Vermicules released from a broken schizont in a lung squash from *Microtus montanus*. Wrights-Giemsa stain, X1,600.

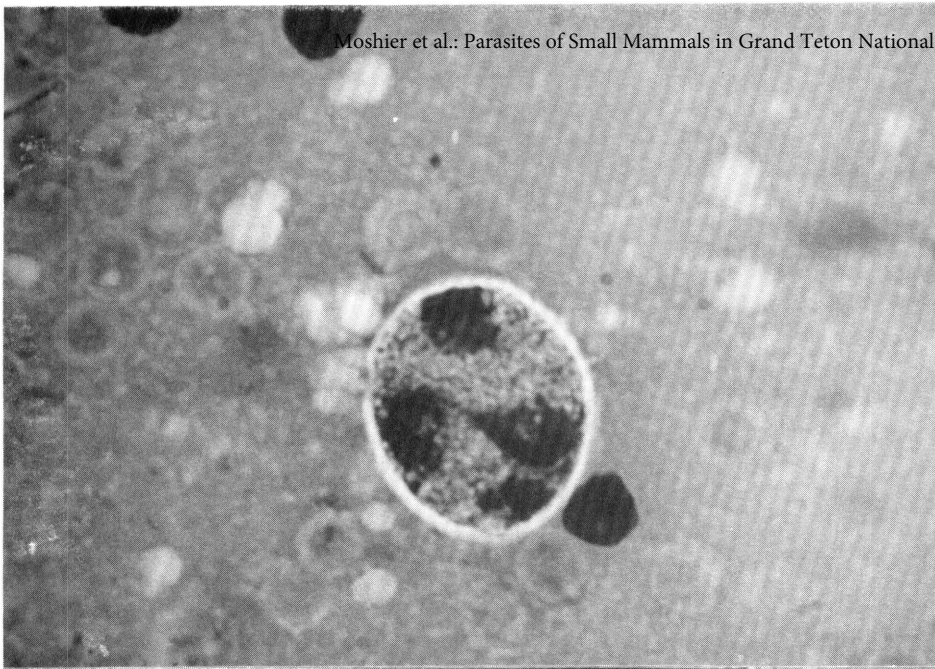


Figure 10. Schizont with 4 nuclei from a liver squash, *Thomomys talpoides*. Wrights-Giemsa stain, X1,600.

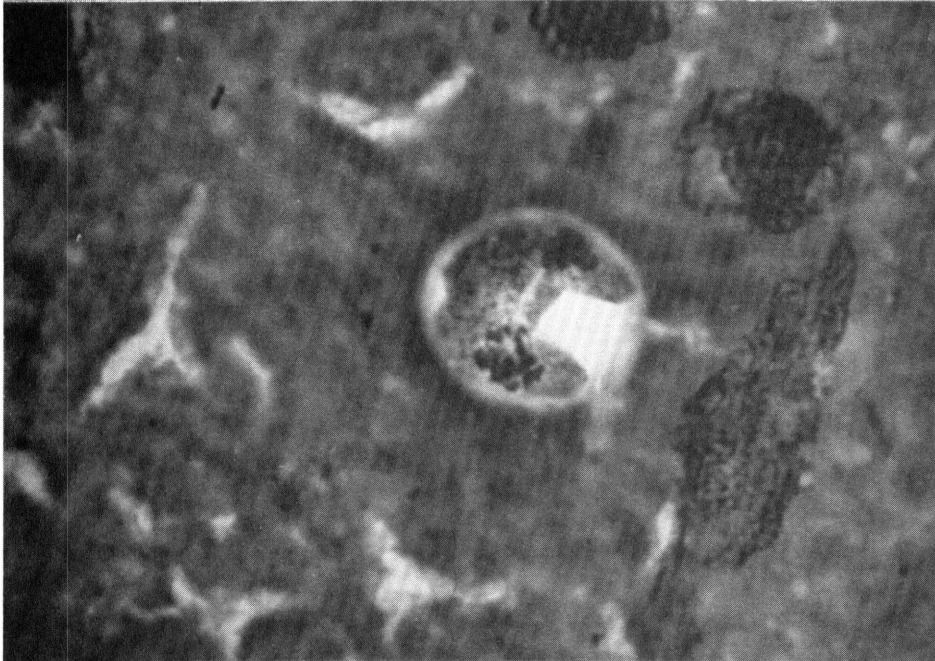


Figure 11. *Thomomys talpoides* liver squash; schizont has 2 nuclei. Wrights-Giemsa, X1,600.

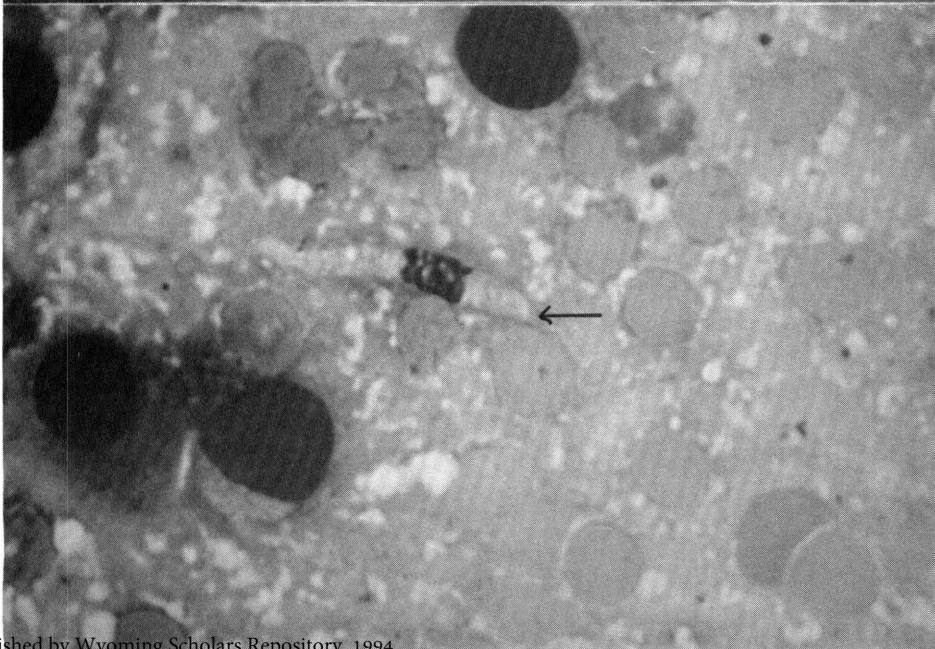

Figure 12. Free vermicule in a lung squash, *Microtus montanus*. Wrights-Giemsa stain, X1,600.

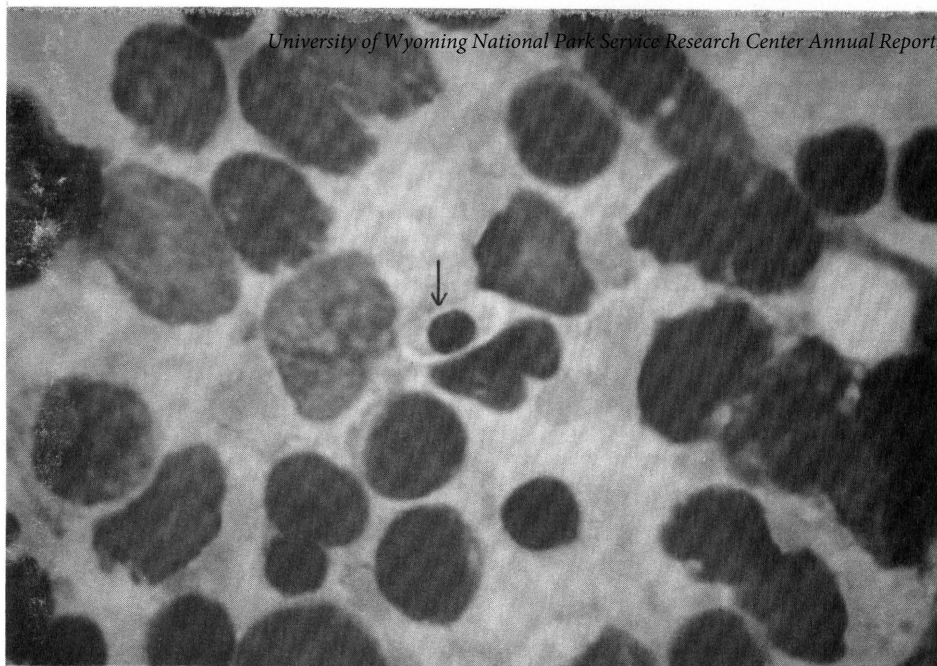

Figure 13.
Gametocyte in a
white blood cell of
the spleen,
*Peromyscus
maniculatus*.
Wrights-Giemsa
stain, X1,600.

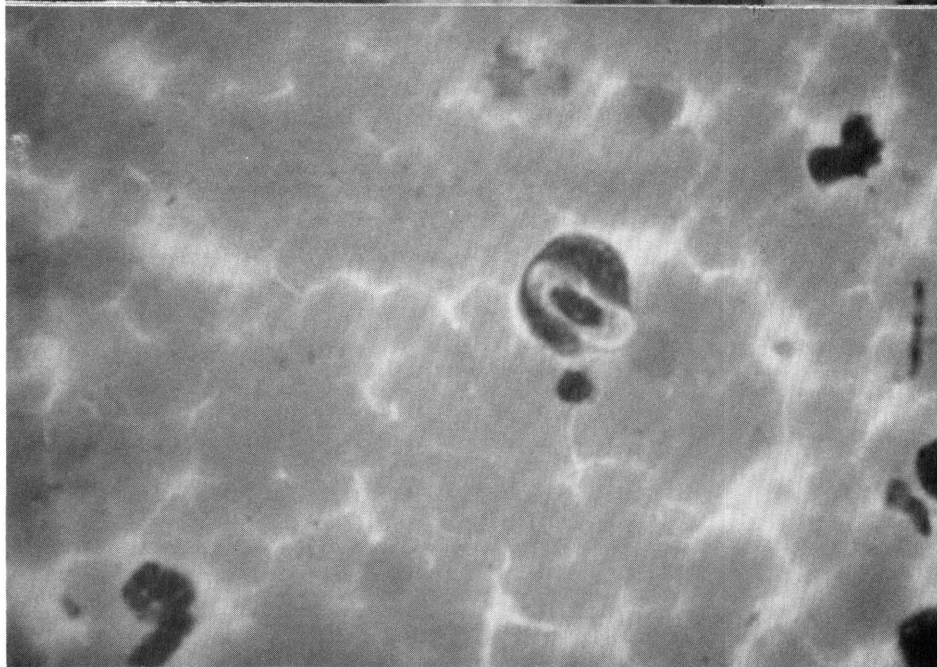


Figure 14.
Gametocyte in a
white blood cell,
blood smear,
Microtus montanus.
Wrights-Giemsa
stain, X1,600.

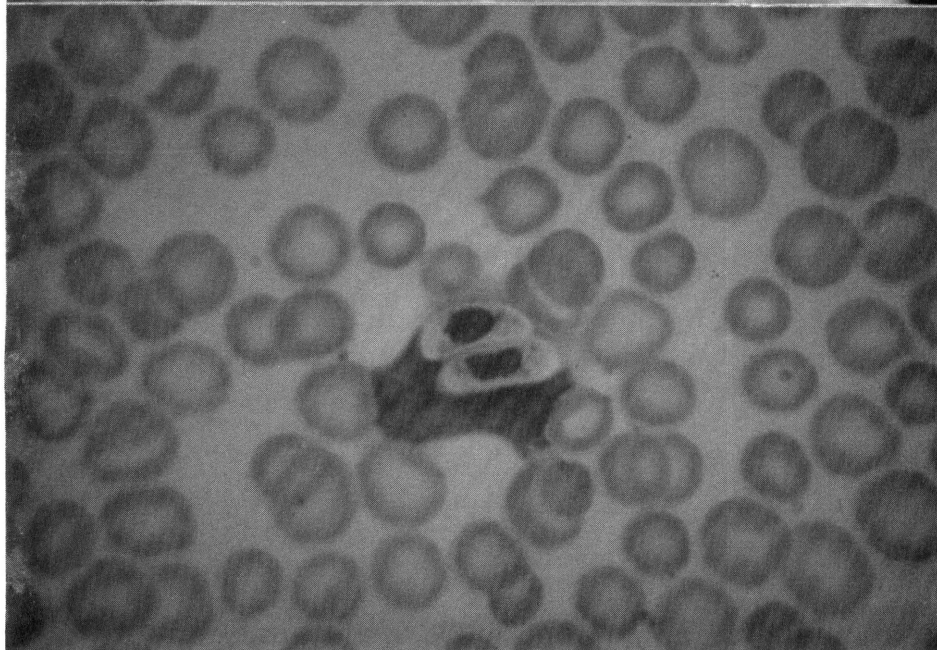


Figure 15. Blood
smear, *Microtus
pennsylvanicus*, with
2 gametocytes.
Wrights-Giemsa
stain, X1,600.

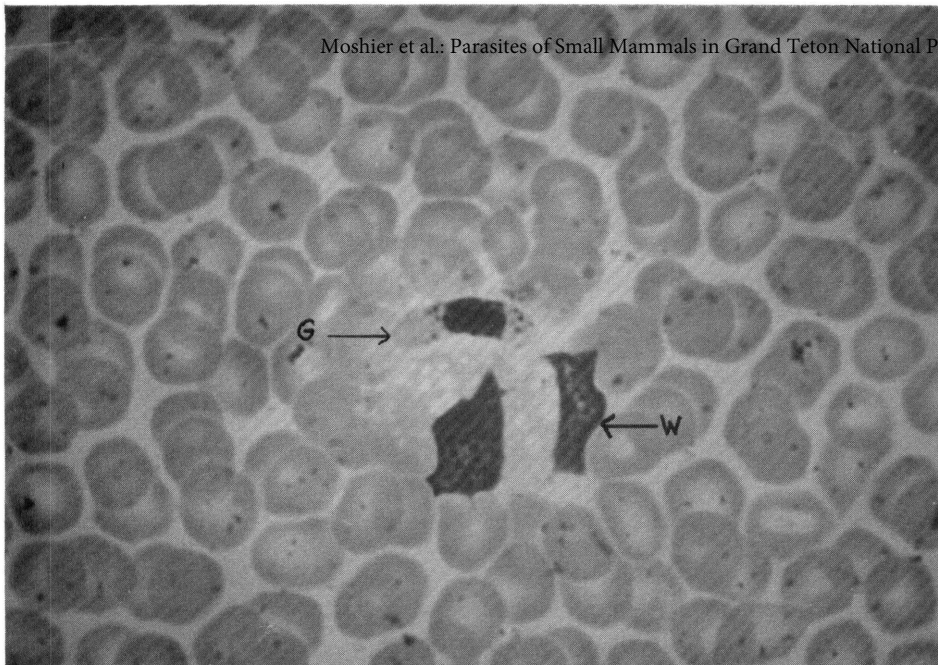


Figure 16.
Gametocyte (G) with
cytoplasmic granules
beside a white blood
cell (W), blood
smear, *Thomomys*
talpoides. Wrights-
Giemsa stain,
X1,600.

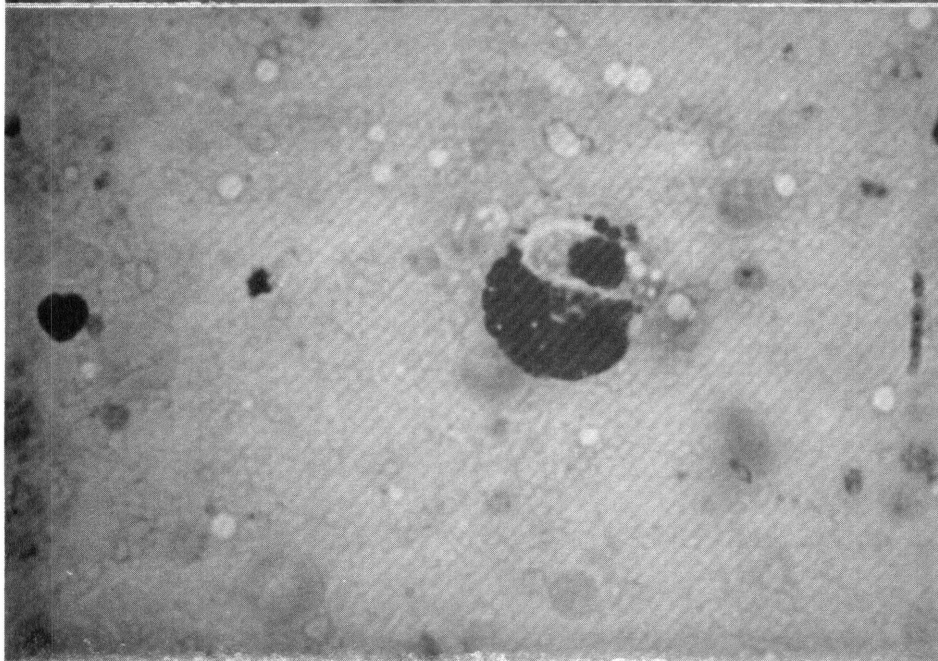


Figure 17.
Gametocyte in a
basophil, liver
squash, *Thomomys*
talpoides. Wrights-
Giemsa stain,
X1,600.

sites. One of the goals of the 1994 study was to determine whether this observation held true. Unfortunately, the population of the *M. montanus* continued to be low, and we found no animals infected with *Hepatozoon*. Krampitz (1964) states that the incidence of *Hepatozoon* infection of voles studied in Europe is directly related to the vole population density.

Since the fleas containing oocysts were squashed beyond recognition, we sought to learn their possible identities by learning which species we had collected from *M. montanus* and preserved intact. In this endeavor we have received excellent help from Dr. Robert E. Lewis of Iowa State University. Five species, collected from 1989 through 1994, have been identified at this time: *Megabothris abantis*, *Megabothris asio megalopus*, *Aetheca wagneri*, *Peromyscopsylla selenis*, and *Hystrichopsylla dippiei dippiei*. *H. dippiei dippiei* and *P. selenis* were collected for the first time in 1994. *H. dippiei dippiei* may be a record for Wyoming. *A. wagneri* is typically associated with *Peromyscus maniculatus*, but does occur on other small rodents (personal communication, R. E. Lewis). It is likely that the invertebrate host for *Hepatozoon* sp. is one or more of these species.

A better understanding of the biology and ecology of these parasites in populations of small mammals will help to establish management programs and public health policies consistent with the public use of National Parks. Information on the prevalence of the parasites and of their vectors is necessary in controlling disease potential in areas where the public may be exposed. As mentioned above, *B. microti* does infect humans. *Hepatozoon* sp. is not known to infect humans, but infections of domestic dogs and cats have been reported (e.g. Craig et al., 1978; Ewing, 1977, and Barton, et al., 1985).

Initial efforts at rearing the tick, *I. eastoni*, were successful. In our first attempts, adult females collected during the summer of 1991 laid their eggs in September. Larvae that hatched from the eggs were allowed to feed on *Babesia*-infected voles. After they molted, they were placed on an uninfected *M. montanus*. Monitoring of blood smears indicated that transmission of the *Babesia* had occurred.

In 1994, only 2 female ticks were collected. They laid eggs and died. Larvae hatched from the

eggs, but only 1 individual would take a blood meal from an infected *M. montanus*. That individual molted, but then refused to feed. All larvae died, presumably from a fungal infection. We plan to devise a way to regulate the humidity in the culture vessels more precisely as a means of preventing the growth of fungi.

◆ ACKNOWLEDGEMENTS

We are grateful to Dr. Robert Lewis, Department of Entomology, Iowa State University, for identifying fleas that we collected and providing other information about fleas. This study was supported in part by a grant from the University of Wyoming. We are grateful for the use of the University of Wyoming-National Park Service Research Center facilities, where field work was conducted.

◆ LITERATURE CITED

- Barton, C. L., Russo, E. A., Craig, T. M., and Green, R. W. 1985. Canine Hepatozoonosis: A Retrospective Study of 15 Naturally Occurring Animal Hospital Association 21: 125-134.
- Craig, T. M., Smallwood, J. E., Knauer, K. E., and McGrath, J. P. 1978. *Hepatozoon canis* Infection in Dogs: Clinical, Radiographic, and Hematologic Findings. Journal of the Amer. Vet. Assoc. 173: 967-972.
- Desser, S. S., Hong, H., and Martin, D. S. 1995. The Life History, Ultrastructure, and Experimental Transmission of *Hepatozoon catesbiana* N. comb., an Apicomplexan Parasite of the Bullfrog, *Rana catesbiana*, and the Mosquito, *Culex territans*, in Algonquin Park, Ontario. Journal of Parasitology 81: 212-222.
- Ewing, G. O. 1977. Granulomatous Cholangiohepatitis in a Cat Due to a Protozoan Parasite Resembling *Hepatozoon canis*. Feline Practice 7: 37-40.

- Krampitz, H. E. 1964. Über das Vorkommen und Verhalten von Haemococcidien der Gattung Hepatozoon, Miller 1908 (Protozoa, Adeleidae) in mittel- und südeuropäischen Säugern. *Acta Tropica* 21: 114-154.
- Pinter, A. J., O'Dell, W. D. and Watkins, R. A. 1988. Intestinal parasites of small mammals from Grand Teton National Park. *Journal of Parasitology* 74(1): 187-188.
- Steketee, T. W., Eckmanm, M. R., Burgess, E. C., Kuritsky, J. N., Dickerson, J., Schell, W. D., Godsey, M. S., and Davis, J. D. 1985. Babesiosis in Wisconsin: A new focus of disease transmission. *Journal of the American Medical Association* 253: 2675-2678.
- Timm, R. M. 1985. Parasites. In: *Biology of New World Microtus*, R. H. Tamarin, ed., Special Publication No. 8, American Society of Mammalogists.
- Watkins, R. A., O'Dell, W. D., Moshier, S. E., and Pinter, A. J. 1992. *Hepatozoon* sp. Infections Found in Three Newly Recognized North American Mammalian Hosts: *Microtus montanus*, *Microtus pennsylvanicus*, and *Thomomys talpoides*. *Proceedings of the Nebraska Academy of Sciences*, p. 44.
- Western, K. A., Benson, G. D., Gleason, N. N., Healy, G. R., and Schulz, M. G. 1970. Human babesiosis in Massachusetts: First case in a patient with a spleen. *New England Journal of Medicine* 283: 854-856.
- Wilson, L. B. and Chowling, W. M. 1904. Studies in *Pyroplasmosis hominis* ("Spotted fever" or "Tick fever" of the Rocky Mountains). *Journal of Infectious Disease* 1: 31-57.